

The task

During several years a patient had been treating the coronary heart disease. Medicamental treatment had no effect. Electrocardiogram didn't show convincing signs of coronary heart disease. The throes arise in the neck and behind the sternum after the meals. The relief came after vomiting and multiple regurgitations. The preliminary diagnosis is: ??? What methods of investigation are necessary to carry out (fulfil) ???

The tests

Contraindication for urgent appendectomy is:

1. Appendicular infiltrate (mass);
2. Myocardial infarction;
3. The second half of pregnancy;
4. Hemorrhagic diathesis;
5. Spreading peritonitis;

From thrombongitis obliterans (Buerger's disease) are mainly suffered ...

1. Women in age of 18-35 years
2. Men in age of 18-35 years
3. Equally men and women before 40
4. Equally men and women after 40
5. Men elder than 40

What is the difference between selective proximal and selective vagotomies?

1. The nerves Laterge are transected
2. The nerves Laterge are preserved
3. Both vagus nerves are transected
4. Intrathoracal vagus nerves transection in one case and intraabdominal their transection in other one.

Operation by Delorm is ...

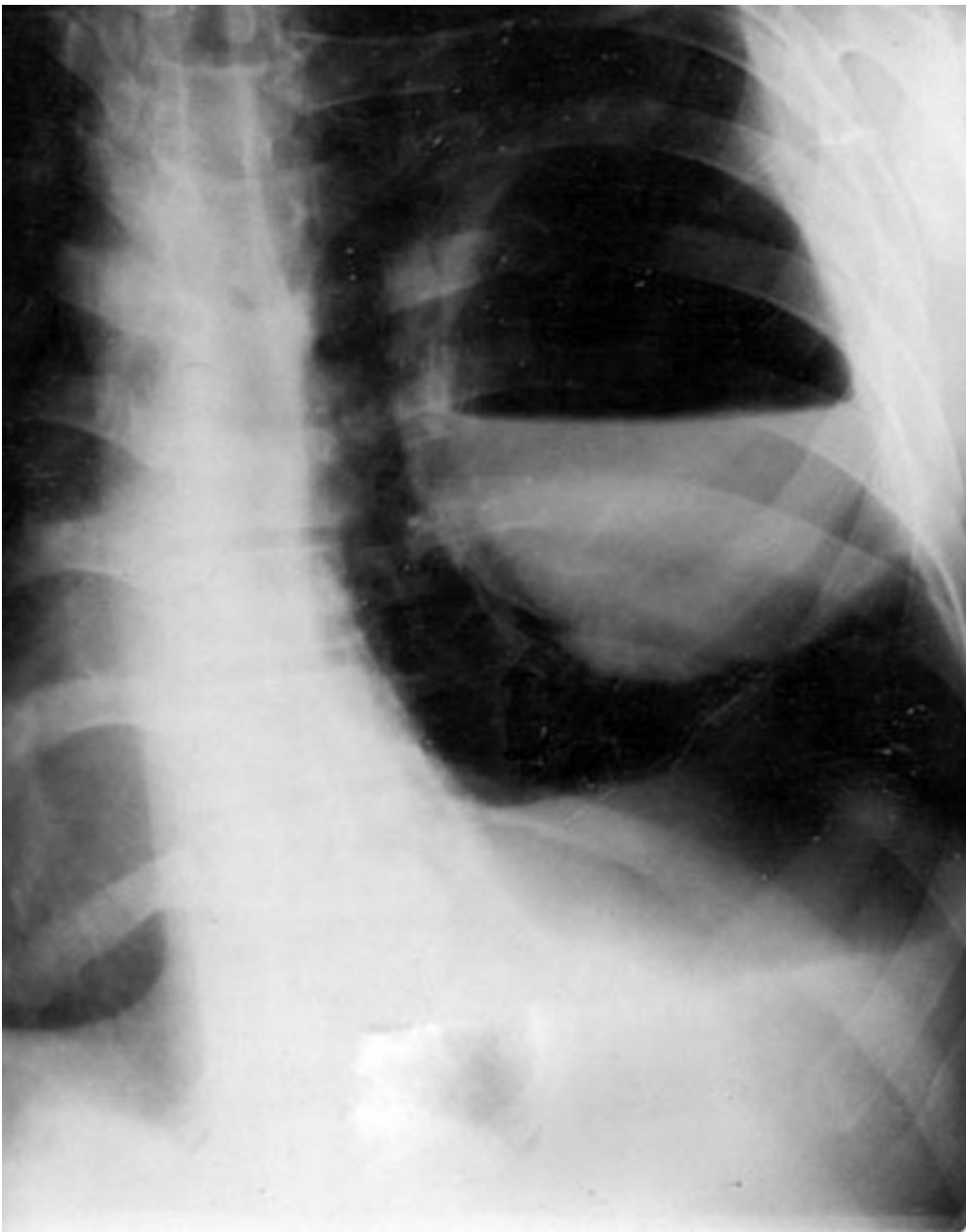
1. Radical pleurectomy and lung decortications
2. Thoracoplasty in local form
3. Thoracotomy with rib resection
4. Pneumonectomy with transtoratic draining
5. Pneumotomy in the middle lobe

Most frequently anal fissura is formed on ...

1. Back hemicircle of anal canal
2. Front hemicircle of anal canal
3. Right hemicircle of anal canal
4. Left hemicircle of anal canal
5. Front and back hemicircle of anal canal

Images Methods of investigations, Diagnosis???

Image 1



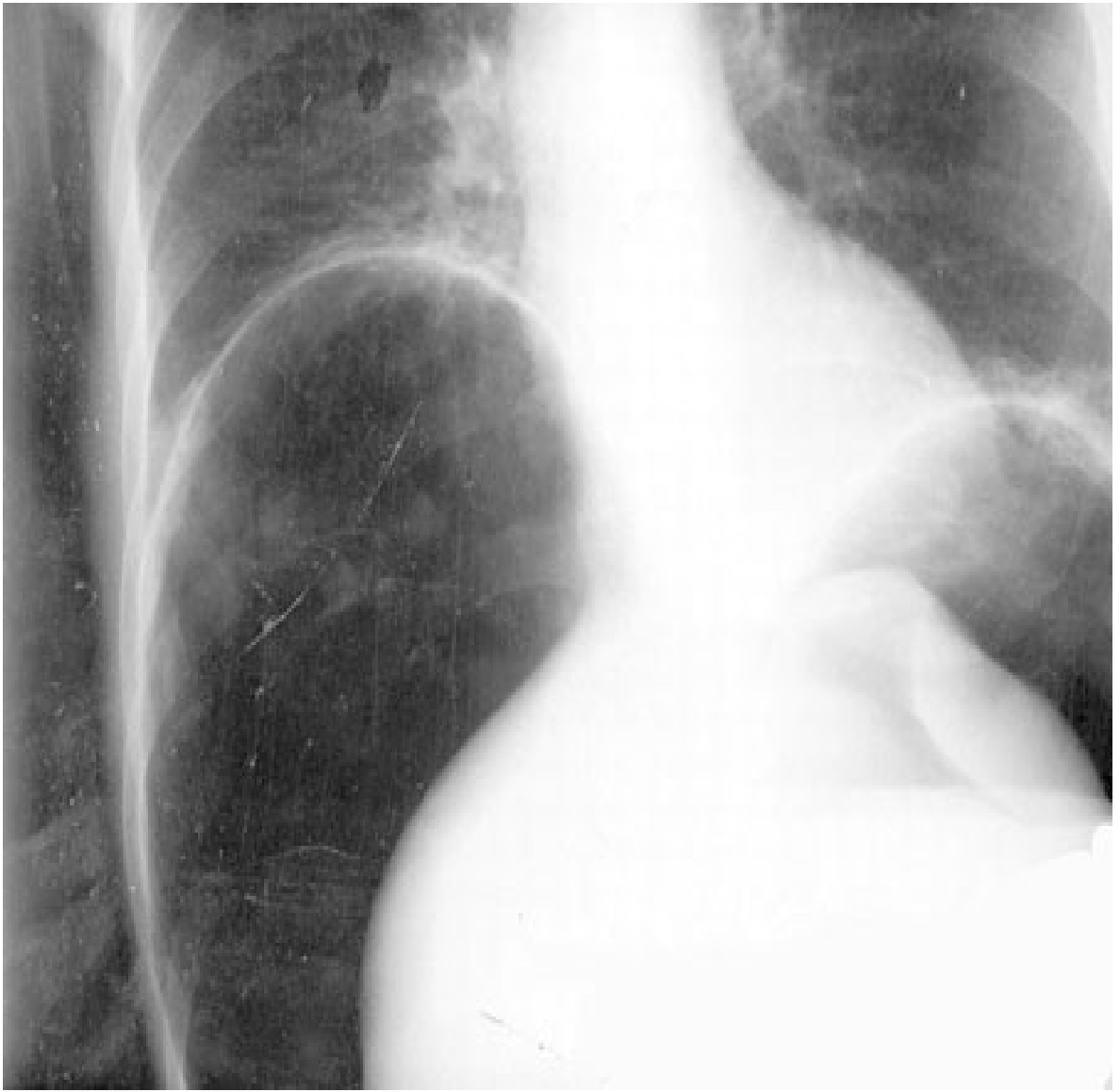


Image 2

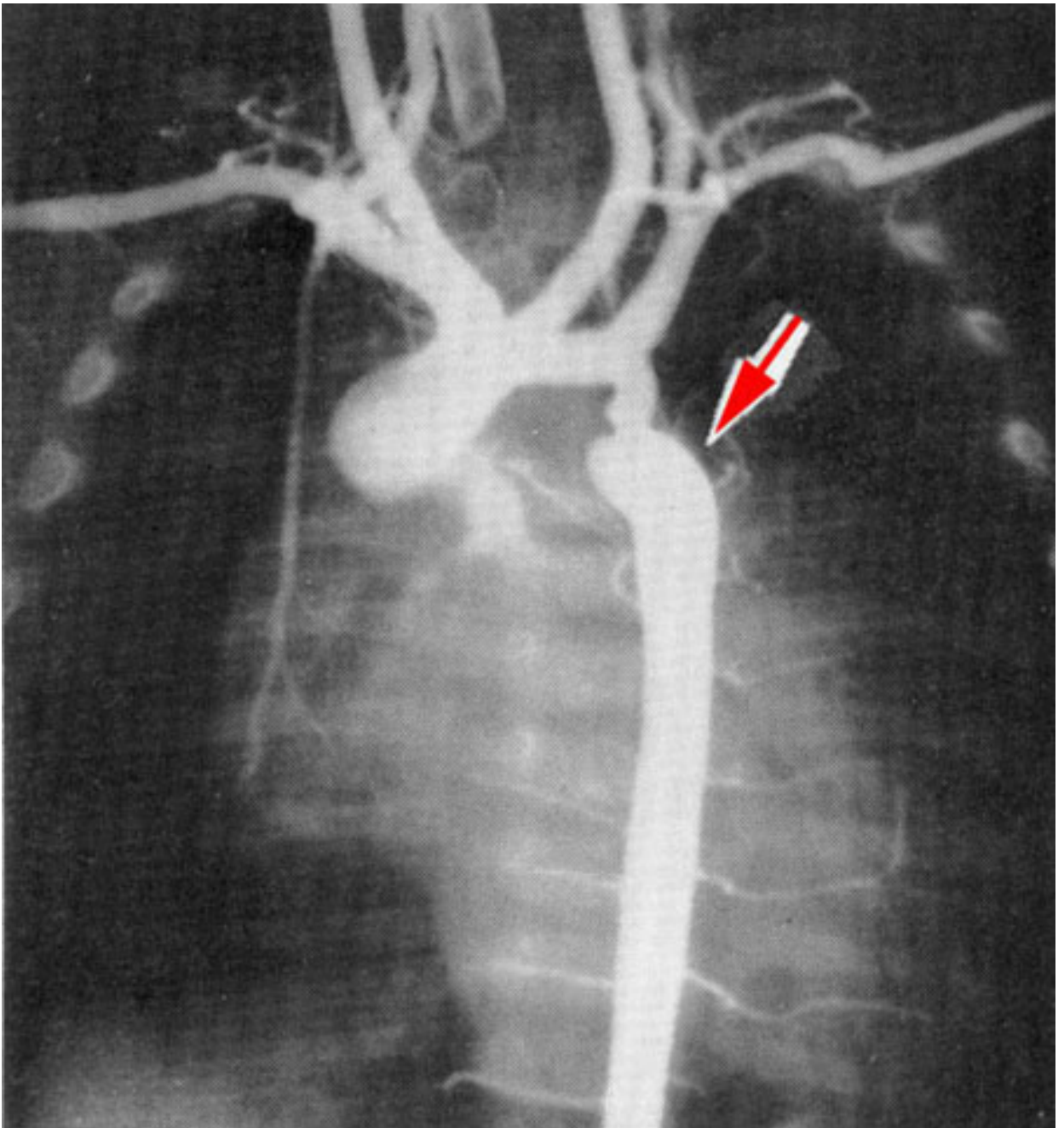


Image 3

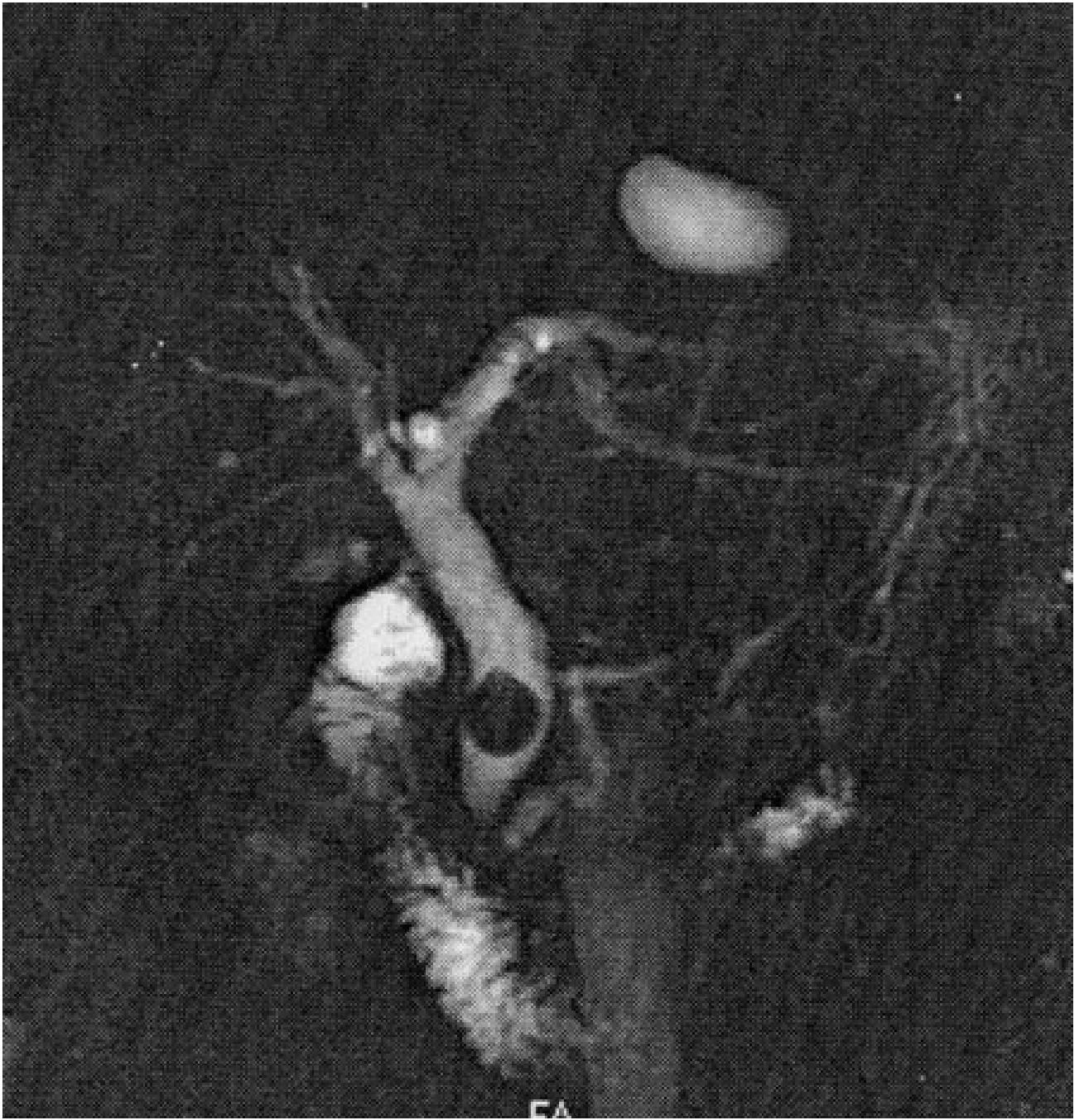

Image 4

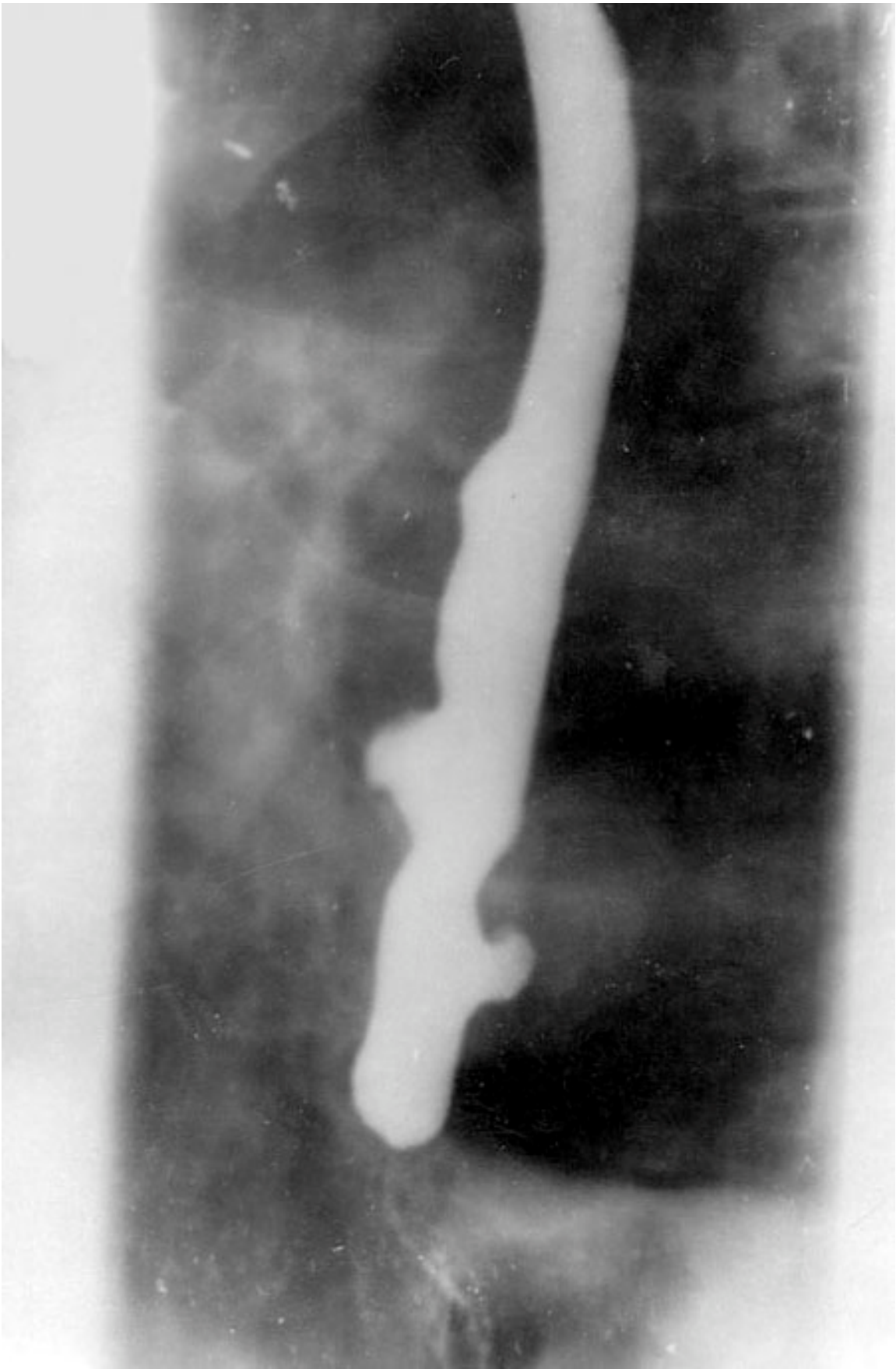


Image 5