

## ***The task***

The patient has chronic pancreatitis for 15 years. What is the simplest way to detect the pancreas calcinosis? What is the tactics in their presence?

## ***The tests***

### **The destructive form of a. appendicitis is:**

1. Apendalgia
2. Perforative
3. Simple
4. Catarrh (catarrhal)
5. Superficial

### **In atherosclerosis obliterans for the first are damaged .....**

1. Microcirculative vessel bed
2. Intraorganic vessels
3. Great (main) arteries of elastic type
4. Great (main) arteries of muscle type
5. Arteriovenous shunts

### **Breast fibroadenoma is the indication for ...**

1. Simple mastectomy
2. Amputation of LG
3. Sectoral resection of LG
4. Radical mastectomy
5. Radiation therapy

### **What damage of aortic valve is the most frequent?**

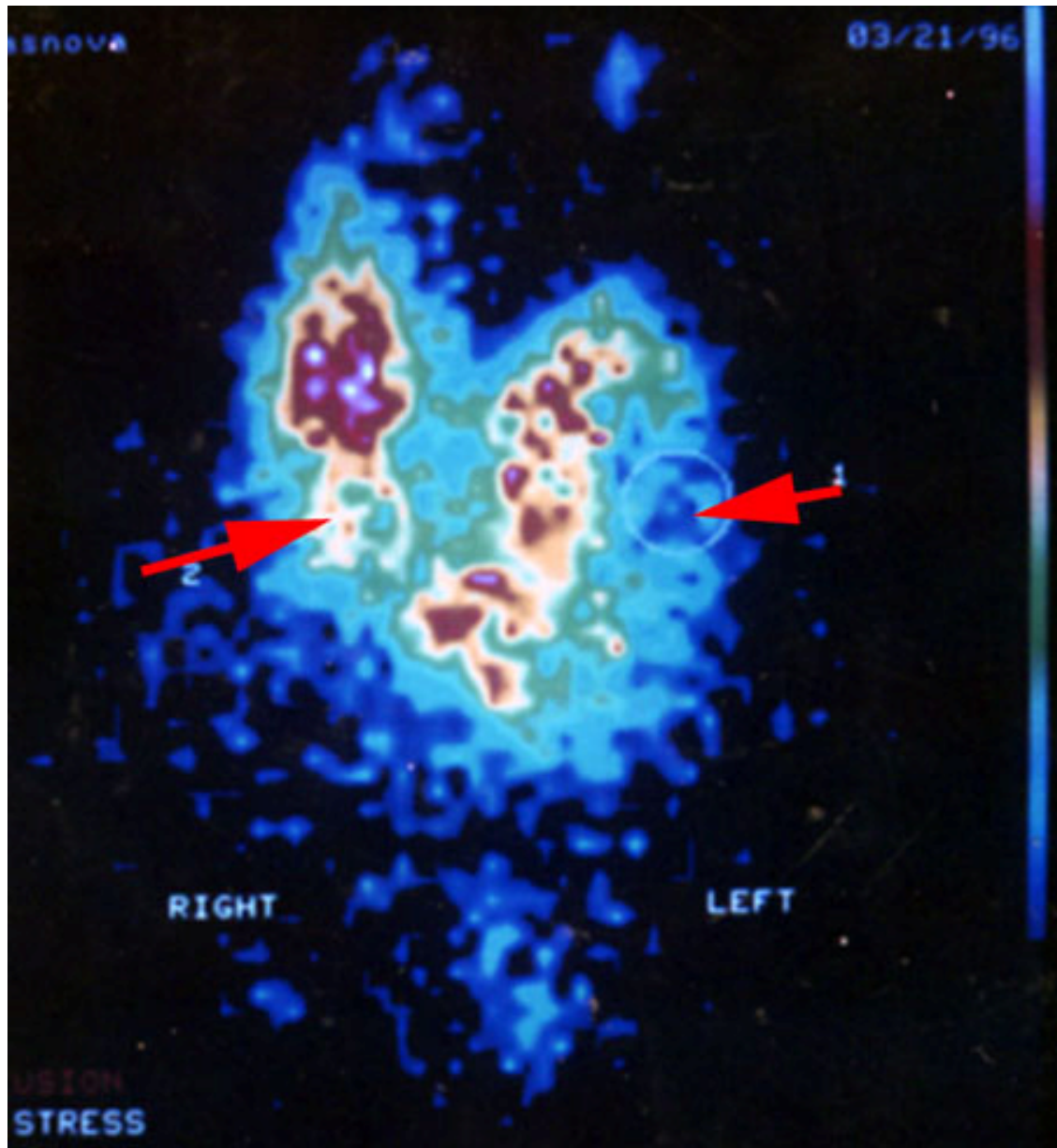
1. Specific
2. Atherosclerotic
3. In septic endocarditis
4. Rheumatic

### **The front wall of the abdominal canal is:**

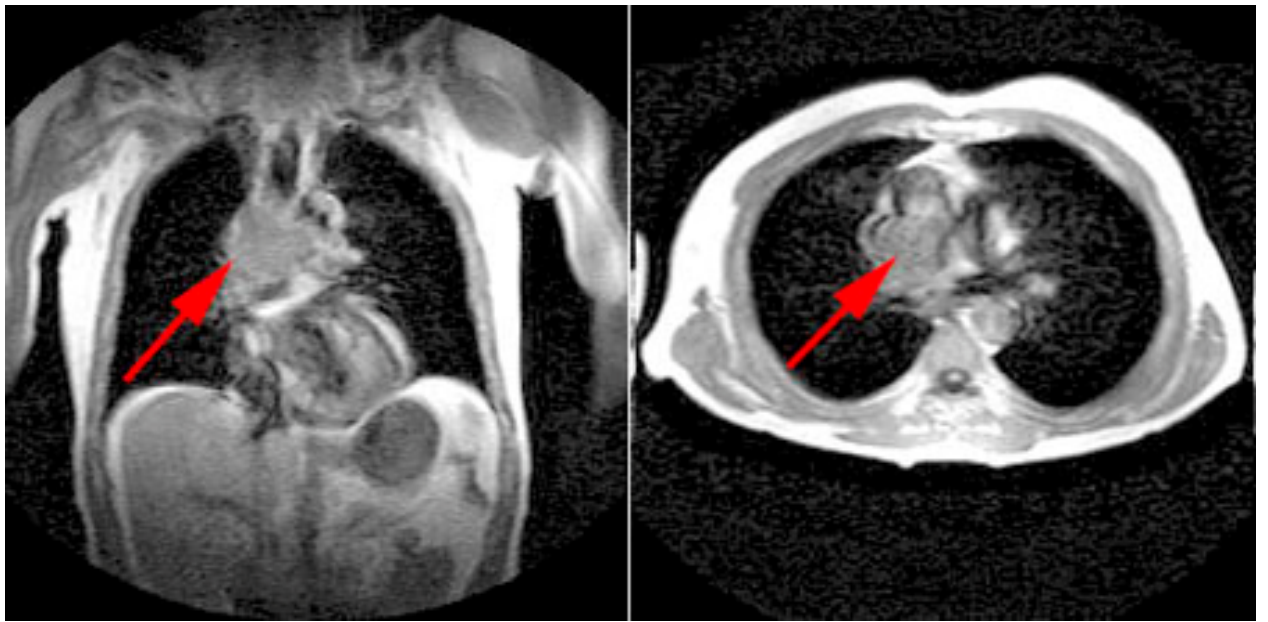
1. Transverse fascia
2. External oblique muscle of abdomen
3. Abdominal (fallopian) ligament
4. A border of the iliac bone

*Images Methods of investigations, Diagnosis???*

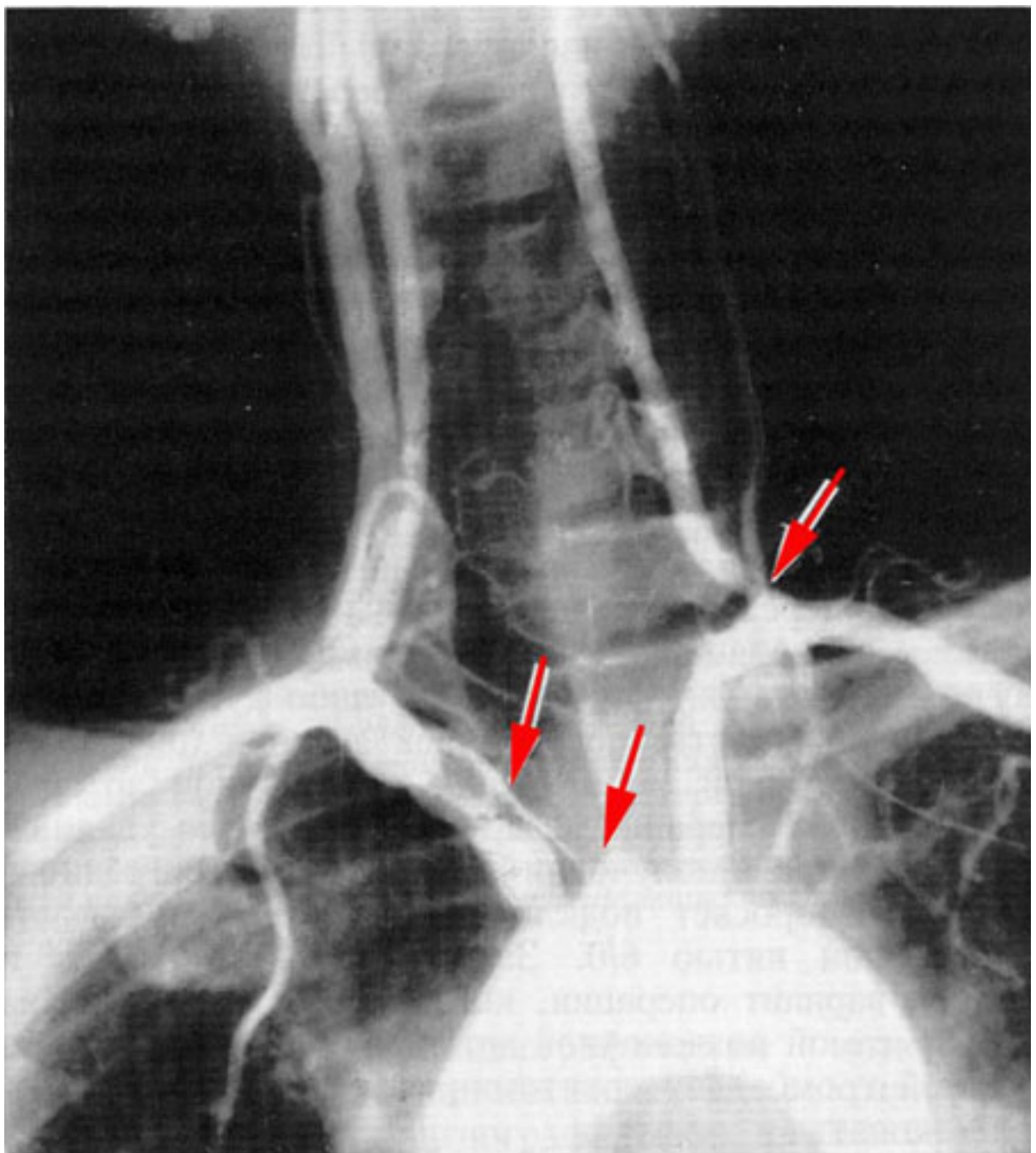
**Image 1**



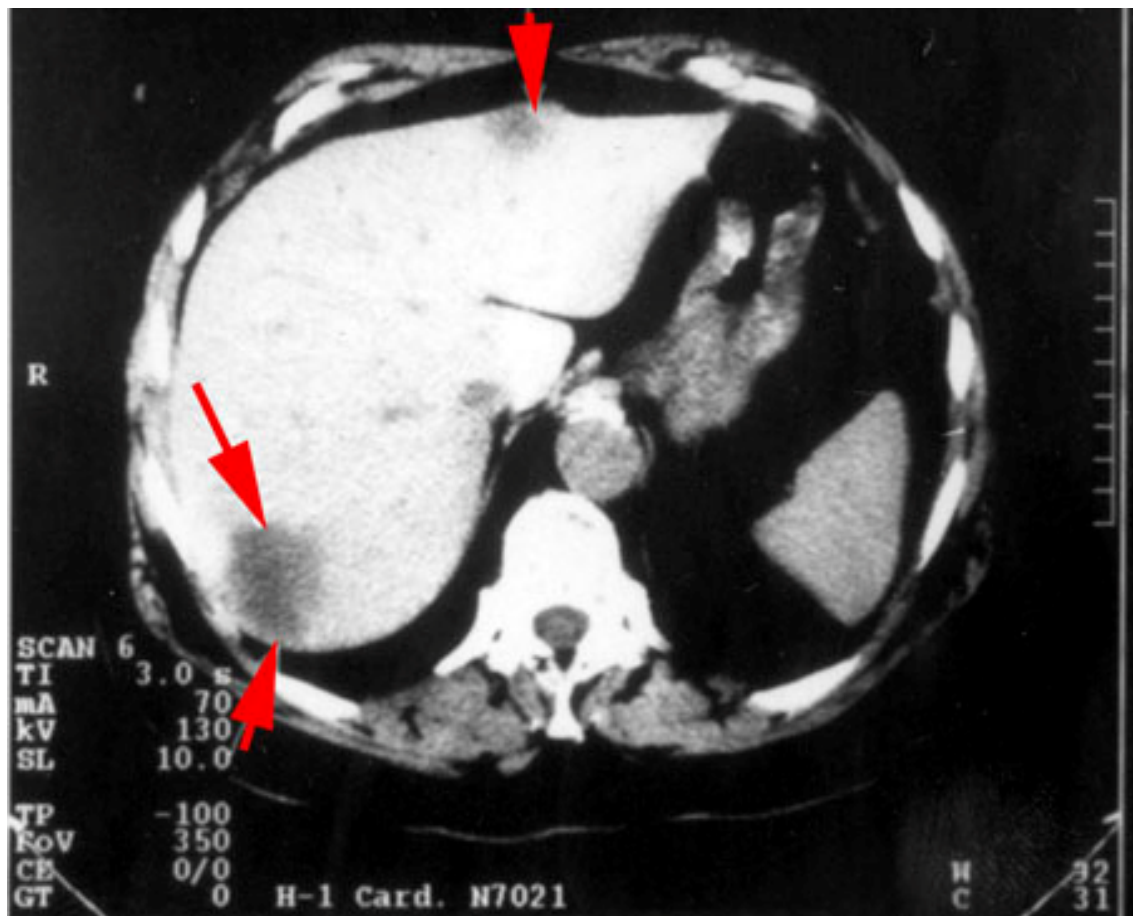
***Image 2***



***Image 3***



**Image 4**



***Image 5***

