

The task

The patient, 40 years old, has been suffering from chronic recurrent pancreatitis for 10 years. During the operation there was suspected pancreas cancer. What are your further actions?

The tests

The main clinical symptom in diagnostics of acute appendicitis is:

1. S-m Koher-Volcovich
2. S-m Rovsing
3. S-m Voskresensky
4. Rasdolsky symptom
5. S-m Schetkin-Blumberg

Where is the place of sapheno-femoral junction?

1. The external ring of the femoral canal
2. 5 sm higher than inguinal ligament
3. 5 sm lower than inguinal ligament
4. Foramen obturatorium
5. The external ring of inguinal canal
6. Besides the radix of scrotum

Clinical manifestation of the stomach cancer is characterized by all, except

1. Stomachaches
2. Anemia
3. Loss weight
4. Rare vomity
5. Bleeding from tumor in late stage of disease

Acute cholecystitis can be complicated by all, except ...

1. Mechanical icterus
2. Portal hypertension
3. Purulent cholangitis
4. Subhepatic abscess
5. Constriction of concrement in papilla Vateri

Treatment of patients with acute bowel obstruction consists of ...

1. Injection of spasmolytics
2. Performing of siphon enema
3. Correction of water – electrolytic disorders
4. Injection of narcotic analgetics

5. Injection of agents for increasing the intestinal motility

Images Methods of investigations, Diagnosis???

Image 1

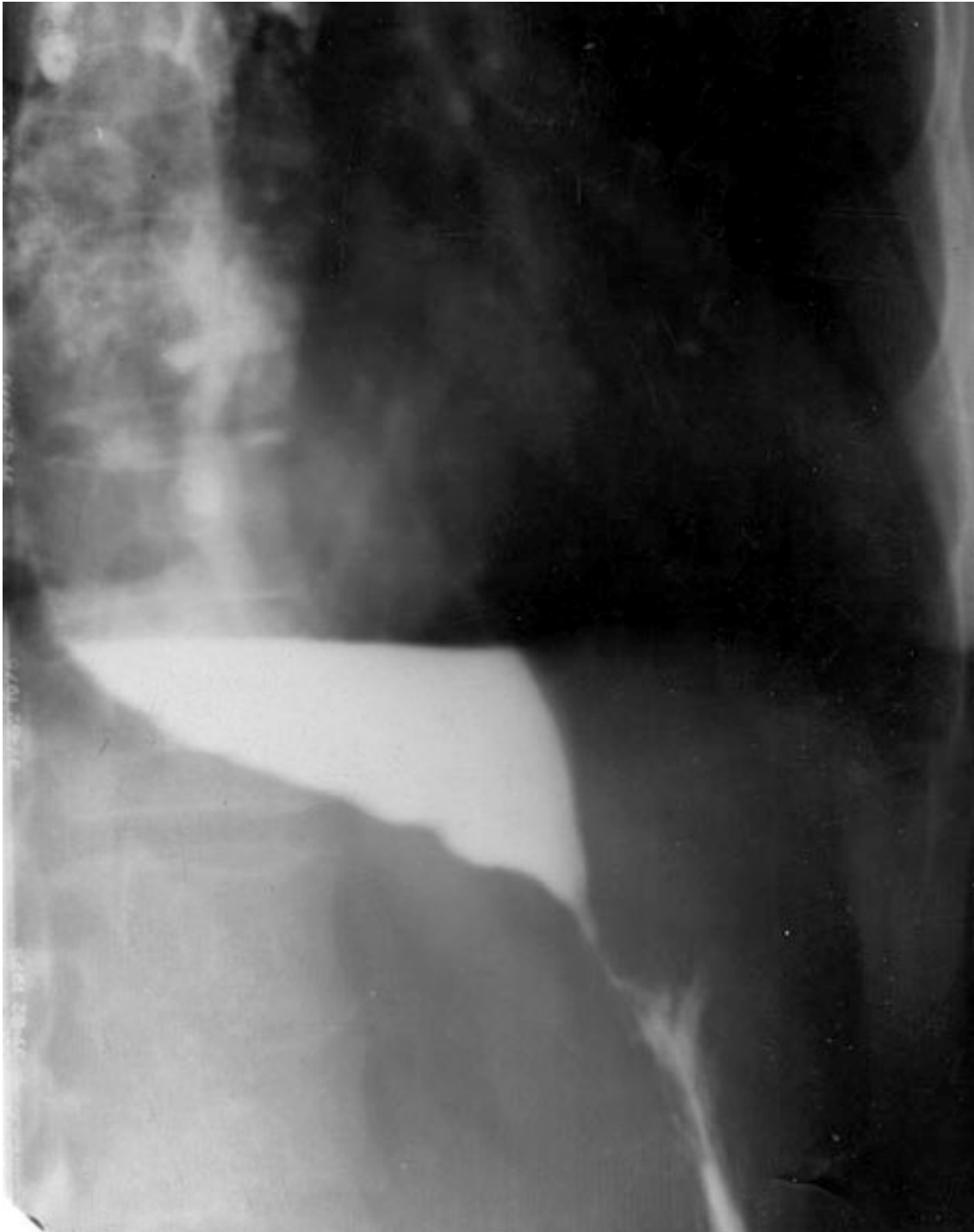


Image 2

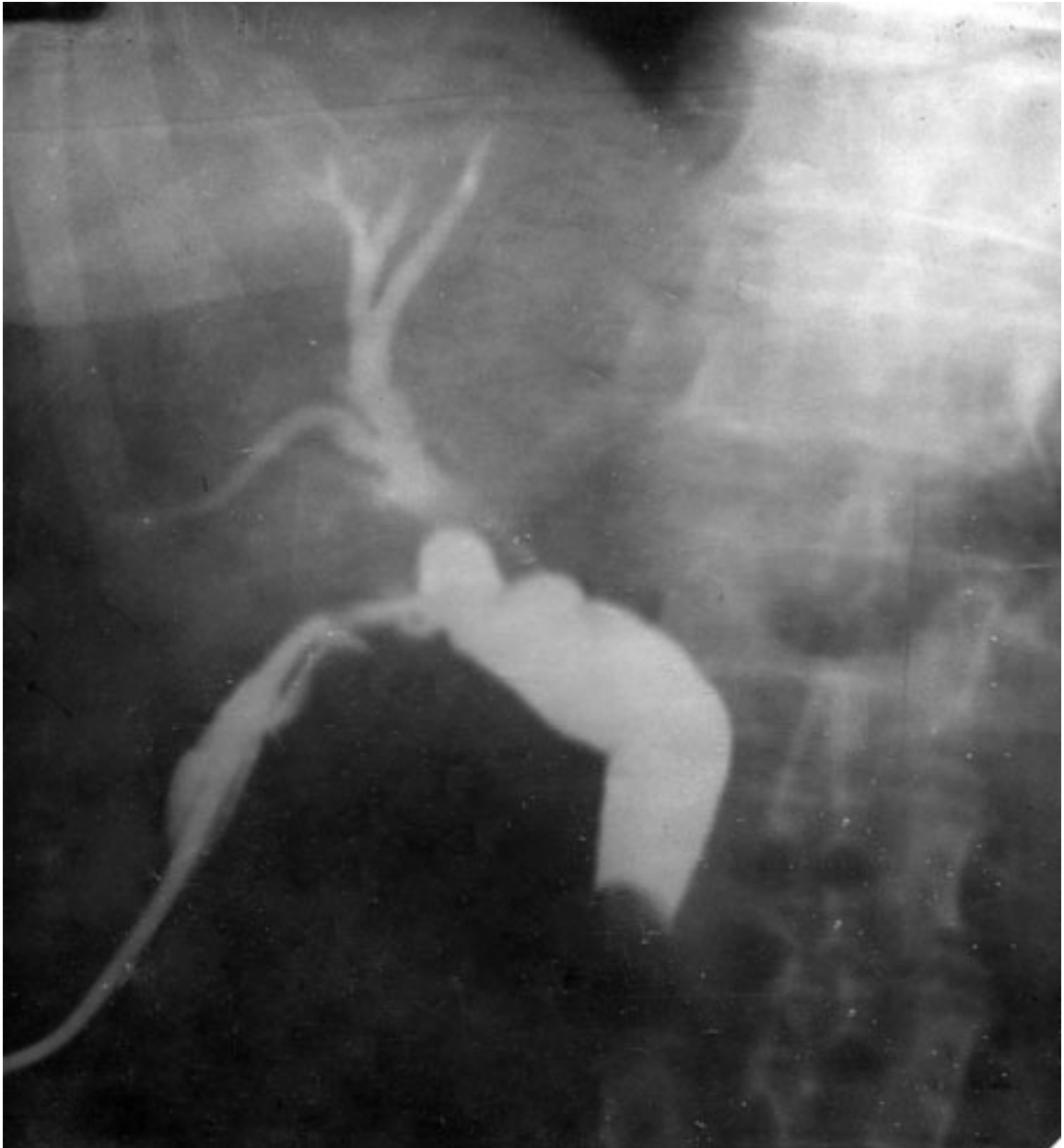


Image 3

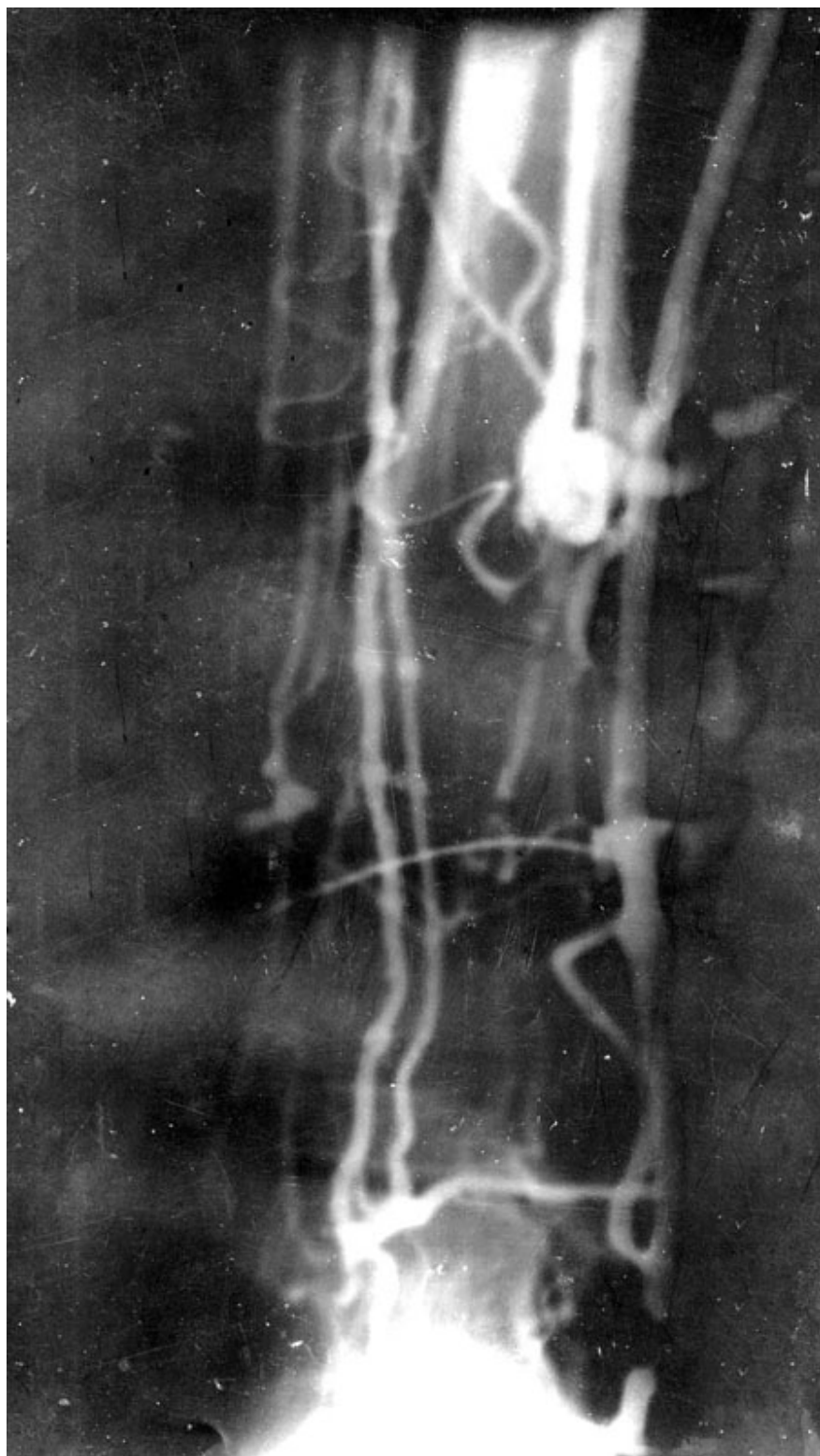

Image 4

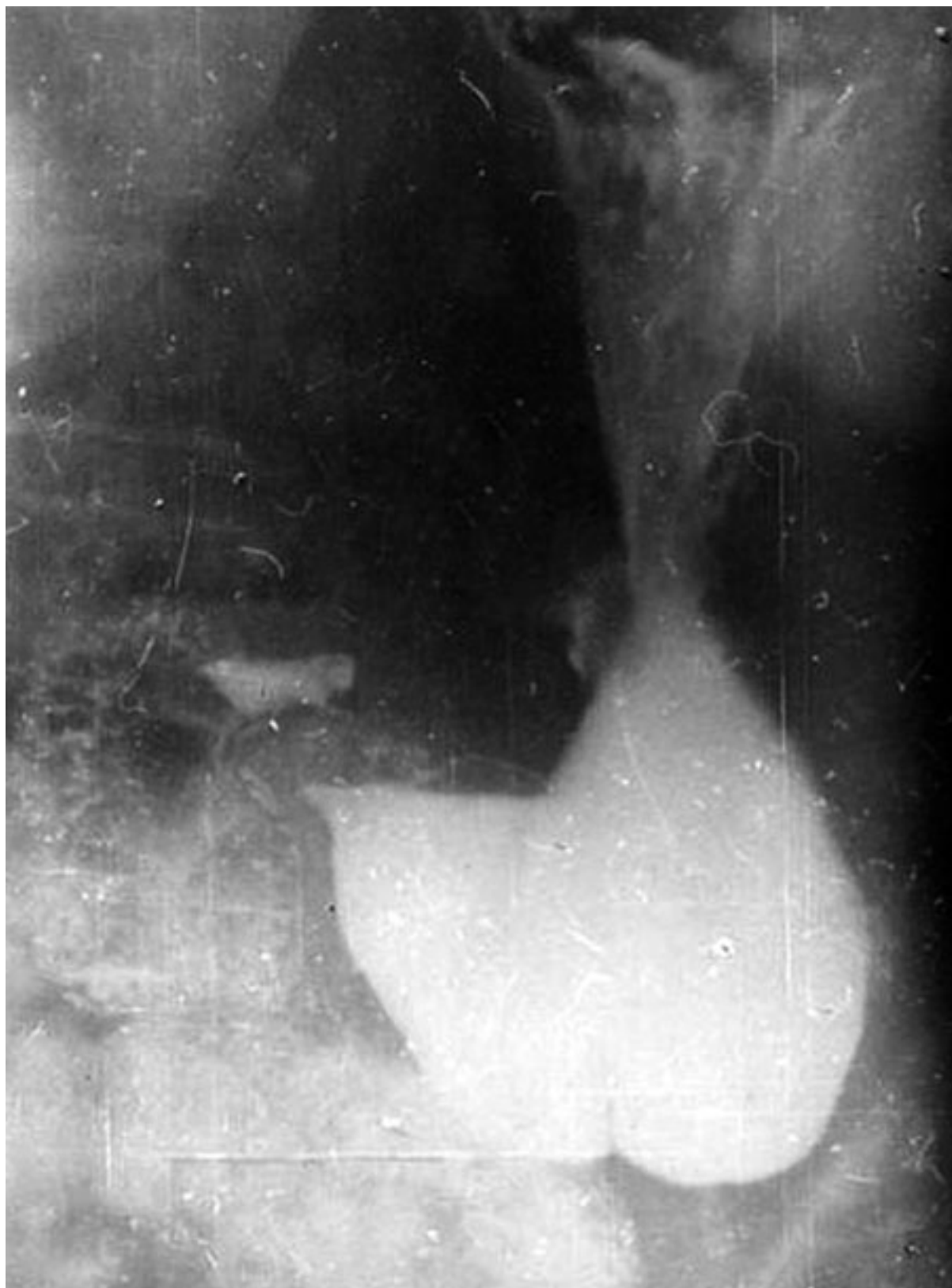

Image 5

