

The task

The patient, 70 years old, has been suffering from the obstructive jaundice for a month. The symptoms are: skin itch, appetite and weight loss. The gallbladder is enlarged, painless. What is the possible diagnosis? How you can ground your opinion?

The tests

Acute ileo-femoral venous thrombosis can be complicated by

1. Thrombemboly of the lung artery
2. Muscle contracture
3. Postthrombotic disease
4. Femoral phlegmone
5. "Crash" syndrome

What Richter's incarceration is?

1. Constriction of bowel in duodenojejunal passage
2. Strangulation of valvuled sigmoid gut
3. Incarceration of the contrmesenterial border of gut
4. Constriction of Meckel's diverticulum

The breadth (width) of choledochus is

- | | |
|----------------------|---------------------|
| 1. Lower than 0,5 cm | 4. 1,6 –2,0 cm |
| 2. 0,6 – 1,0 cm | 5. More than 2,0 cm |
| 3. 1,1 – 1,5 cm | |

The cause of shock state and collapse in patients with acute pancreatitis is ...

1. Pancreatogenic peritonitis
2. Compression of the distal part of choledochus and cholemia
3. Enzymatic toxemia
4. Biliary hypertension
5. Dinamic bowel obstruction

What complication is the rarest one in patients with ulcer of duodenum?

1. Perforation
2. Malignization
3. Bleeding
4. Stenosis
5. Penetration

Images Methods of investigations, Diagnosis???

Image 1

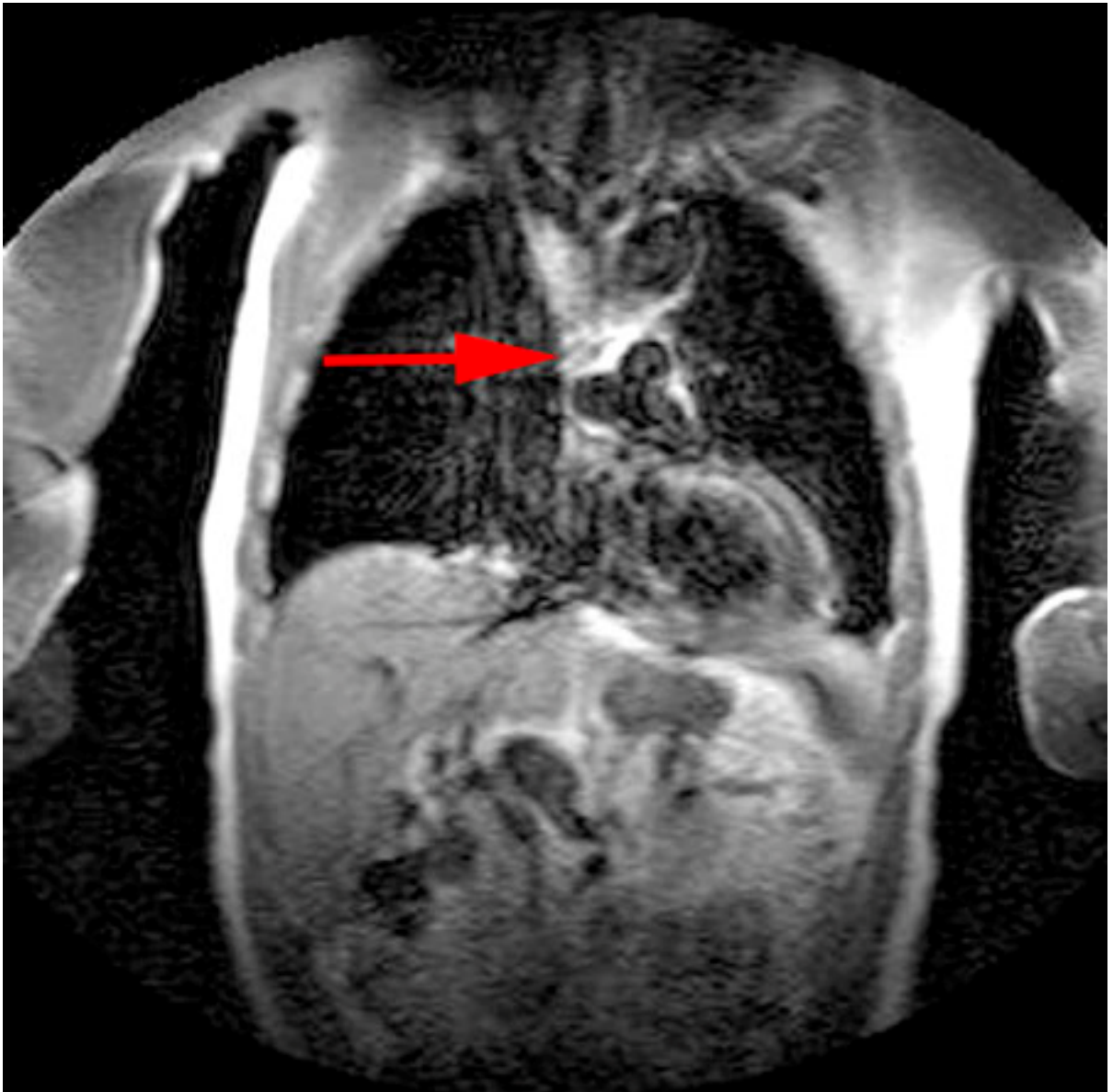


Image 2

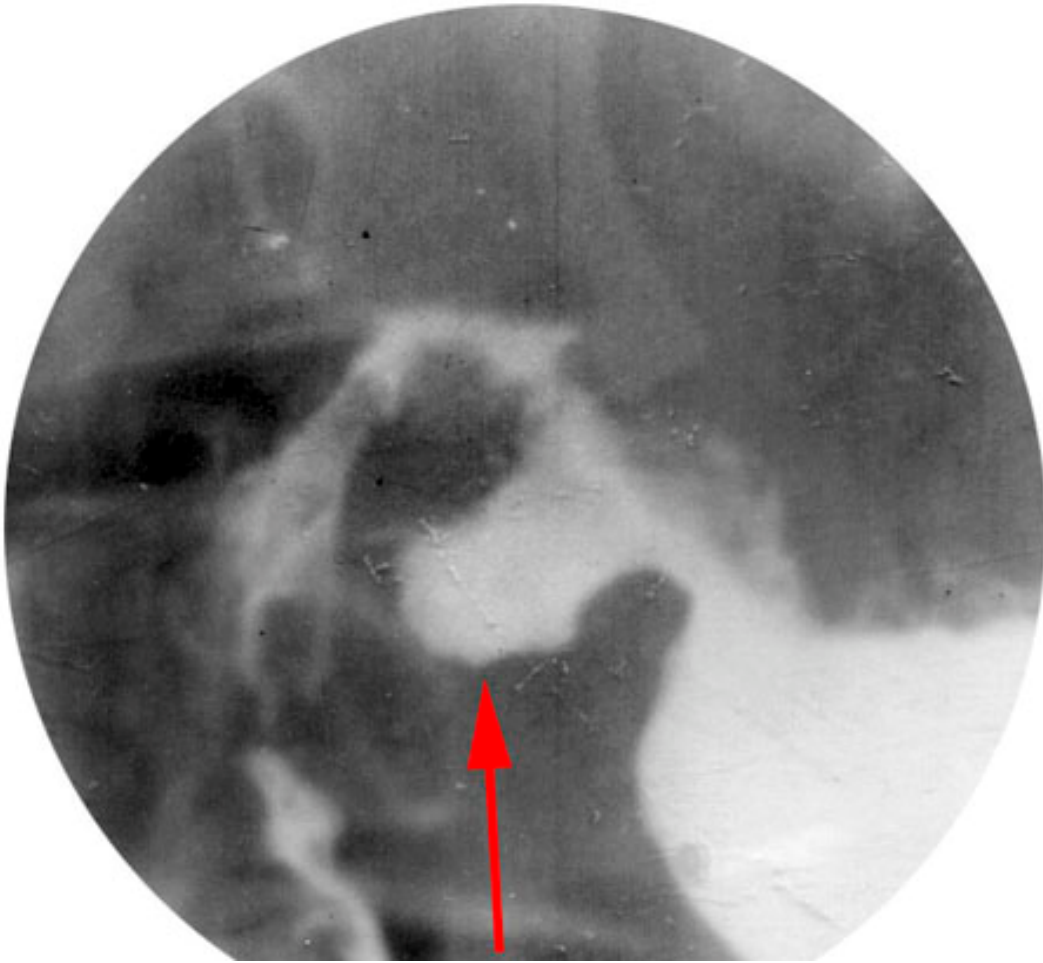

Image 3

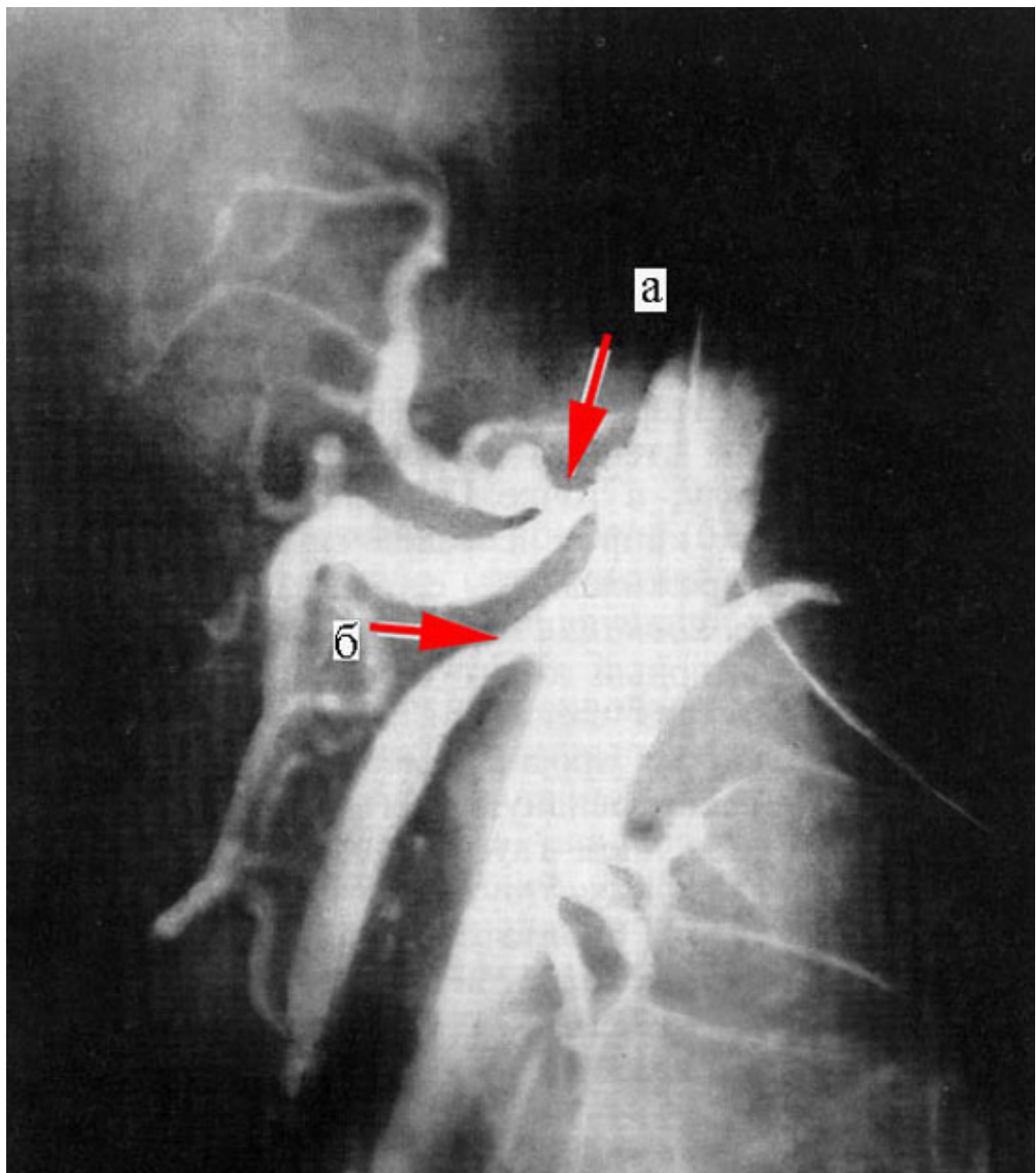


Image 4

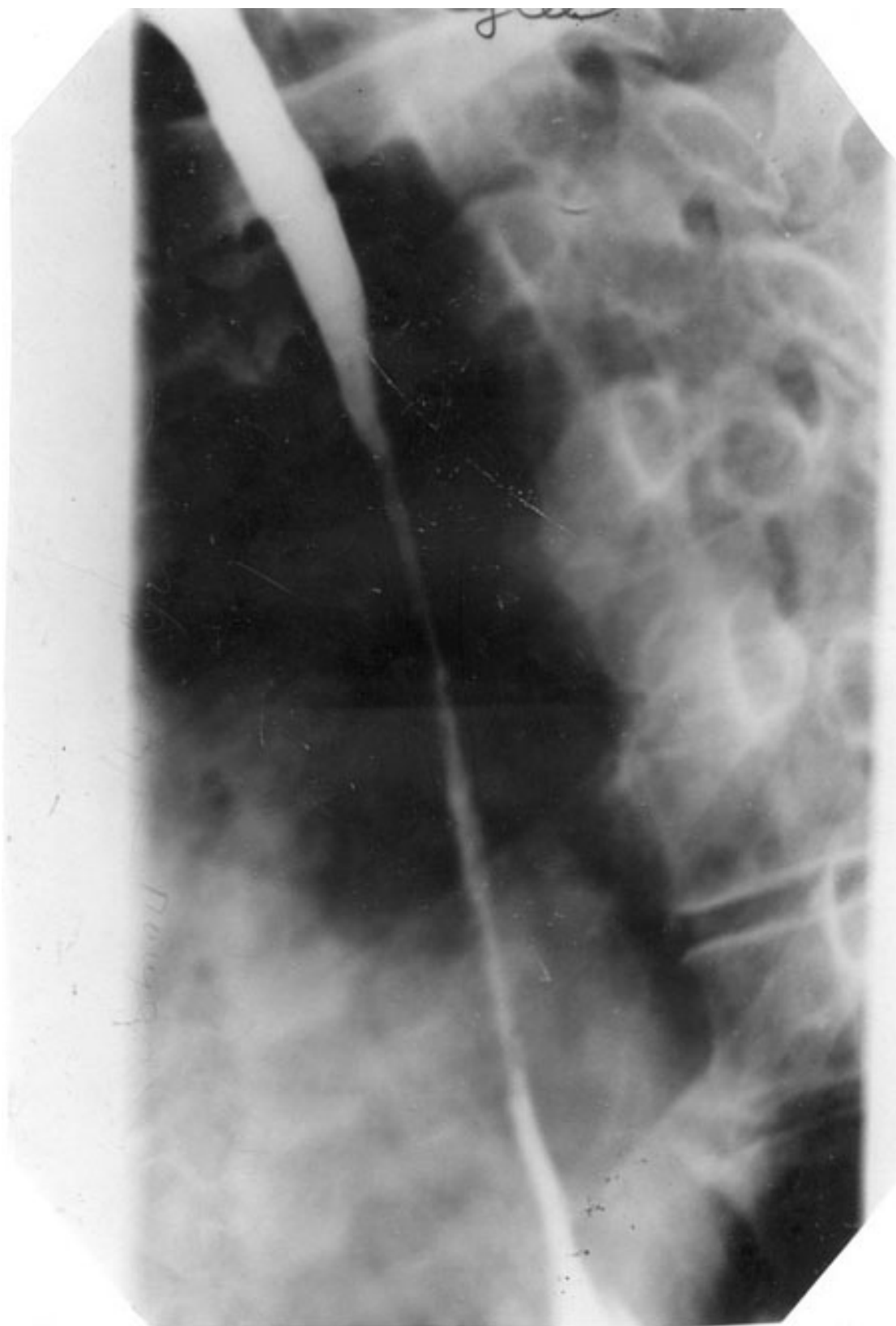


Image 5

