

The task

The patient had cholecystectomy for the calculous cholecystitis two years ago. 6 months later there appeared pains in the right hypochondrium and dark urine. Bilirubin is 120 $\mu\text{mol/l}$. The method of diagnosing for the obstacle level is? What is the tactics of surgeon in this case?

The tests

The causes of gastro-intestinal bleeding are:

1. Gastro-duodenal ulcerative disease
2. Disease of Delafua
3. Acute cholecystitis
4. Maloyri-Weiss syndrome
5. All of them

The prophylaxy of endemic goiter is consisted of ...

1. Salt iodine supplementation
2. Replacement with thyroid hormones
3. Using of antistruin in pregnant women and children
4. All of them
5. None of them

The main cause of lung abscess is

1. Pneumonia
2. Aspiration
3. Influenza
4. Trauma
5. Unknown

There are physiological constrictions of esophagus

1. Four
2. One
3. Three
4. Two
5. Five
6. There are not physiological constrictions in esophagus

The most effective diagnostic method in patients with LG tumors less than 1 cm is...

1. Mammography
2. USD
3. Thermography
4. Palpation
5. Radioisotope diagnostics

Images Methods of investigations, Diagnosis???

Image 1

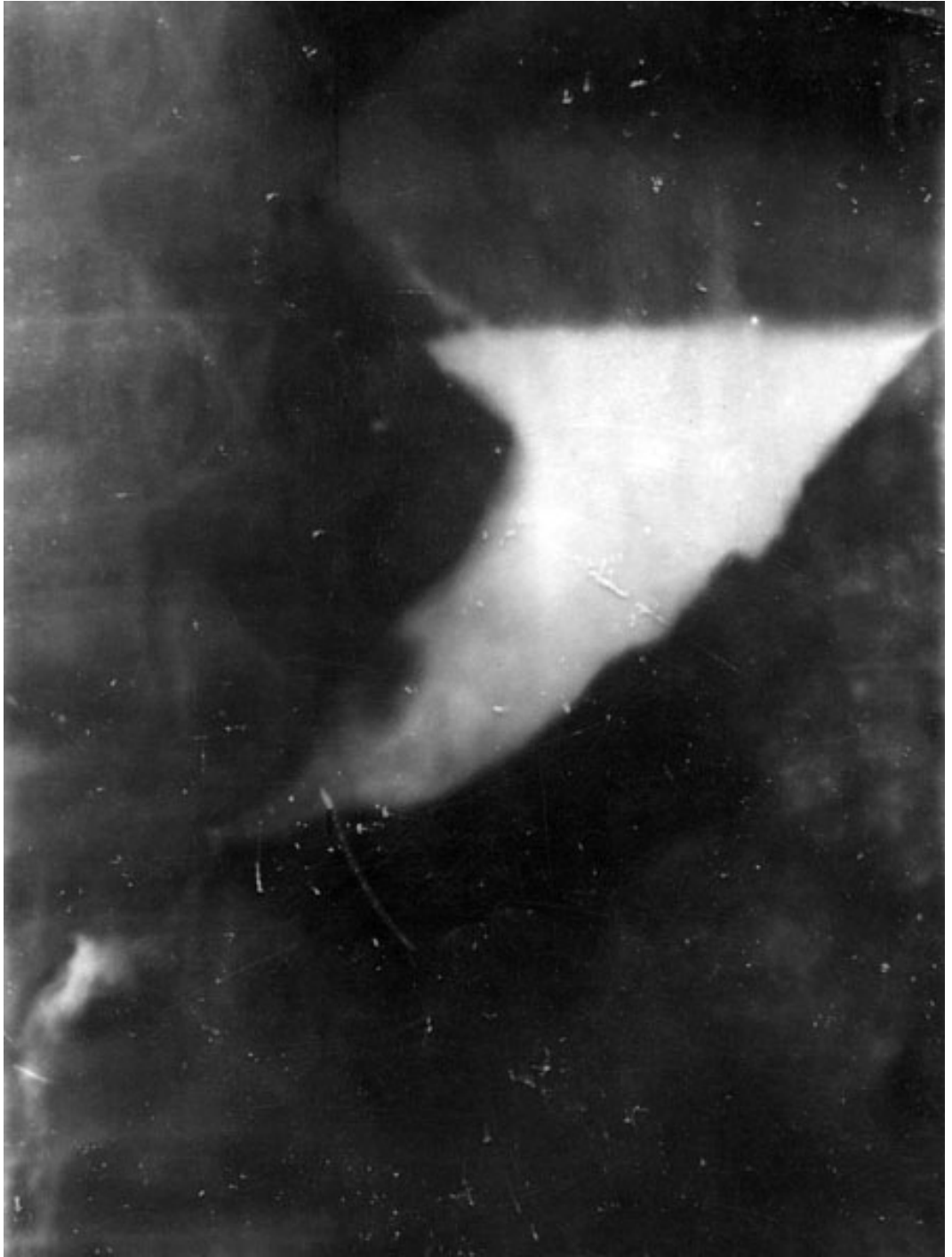

Image 2

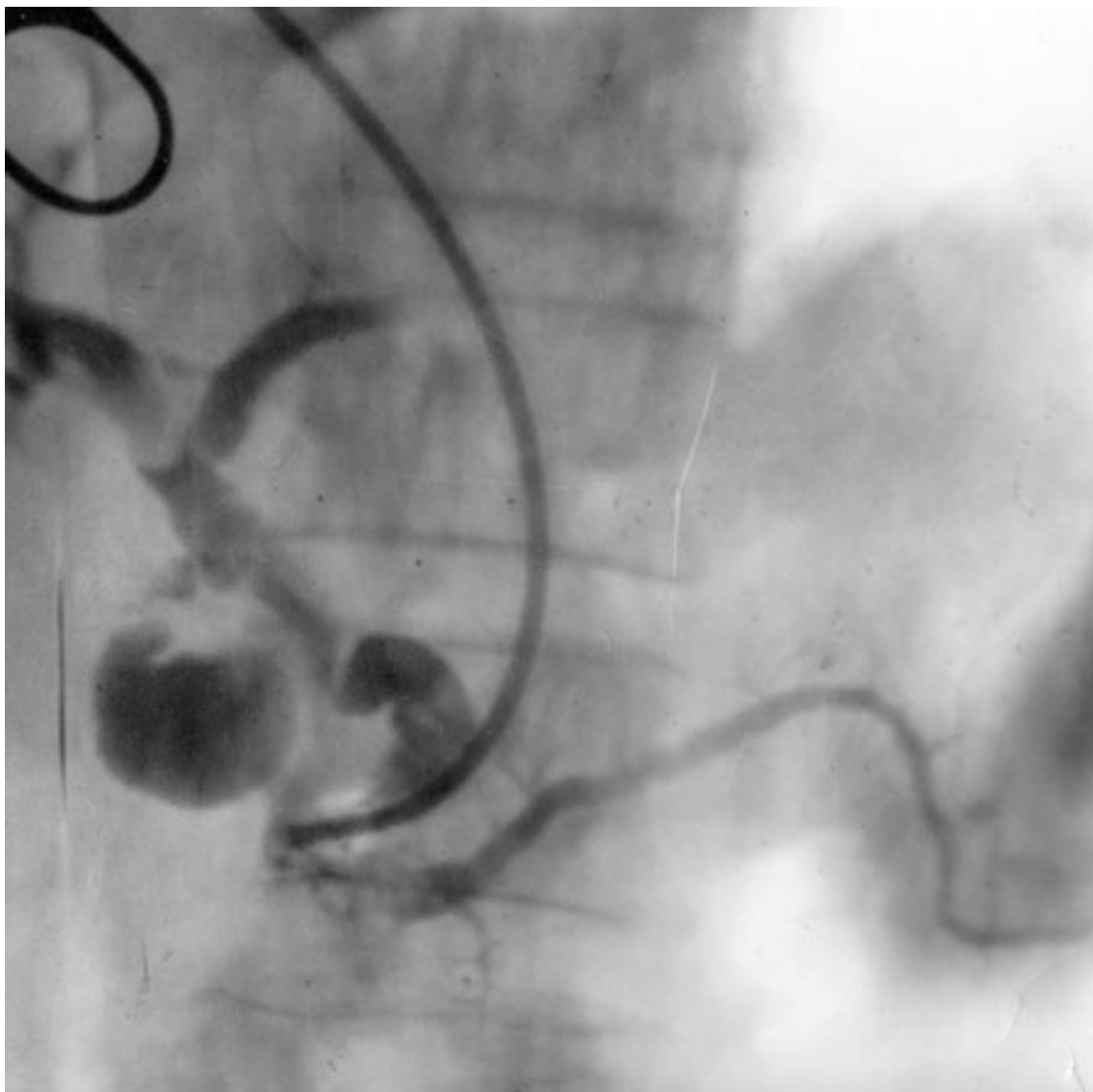


Image 3

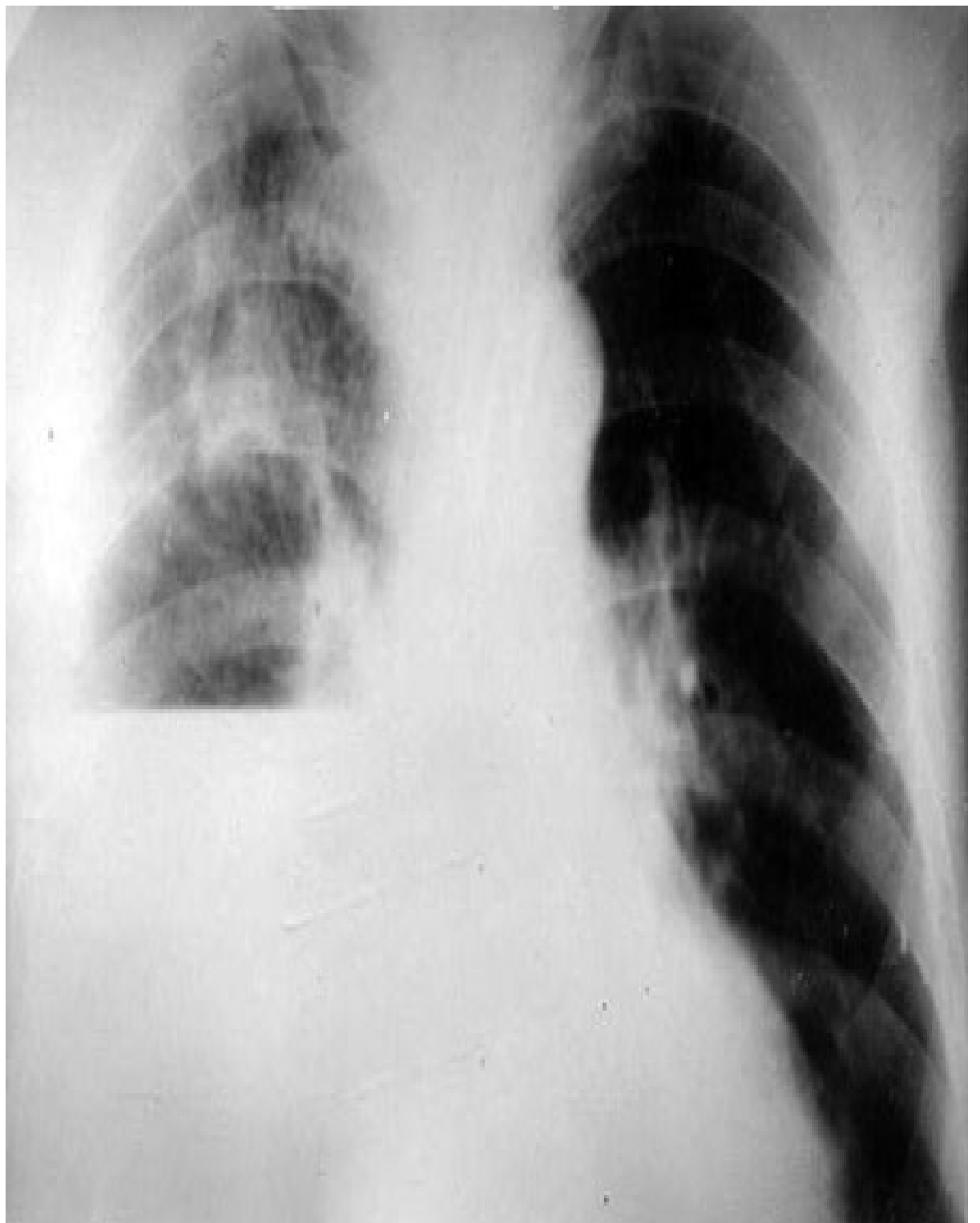


Image 3

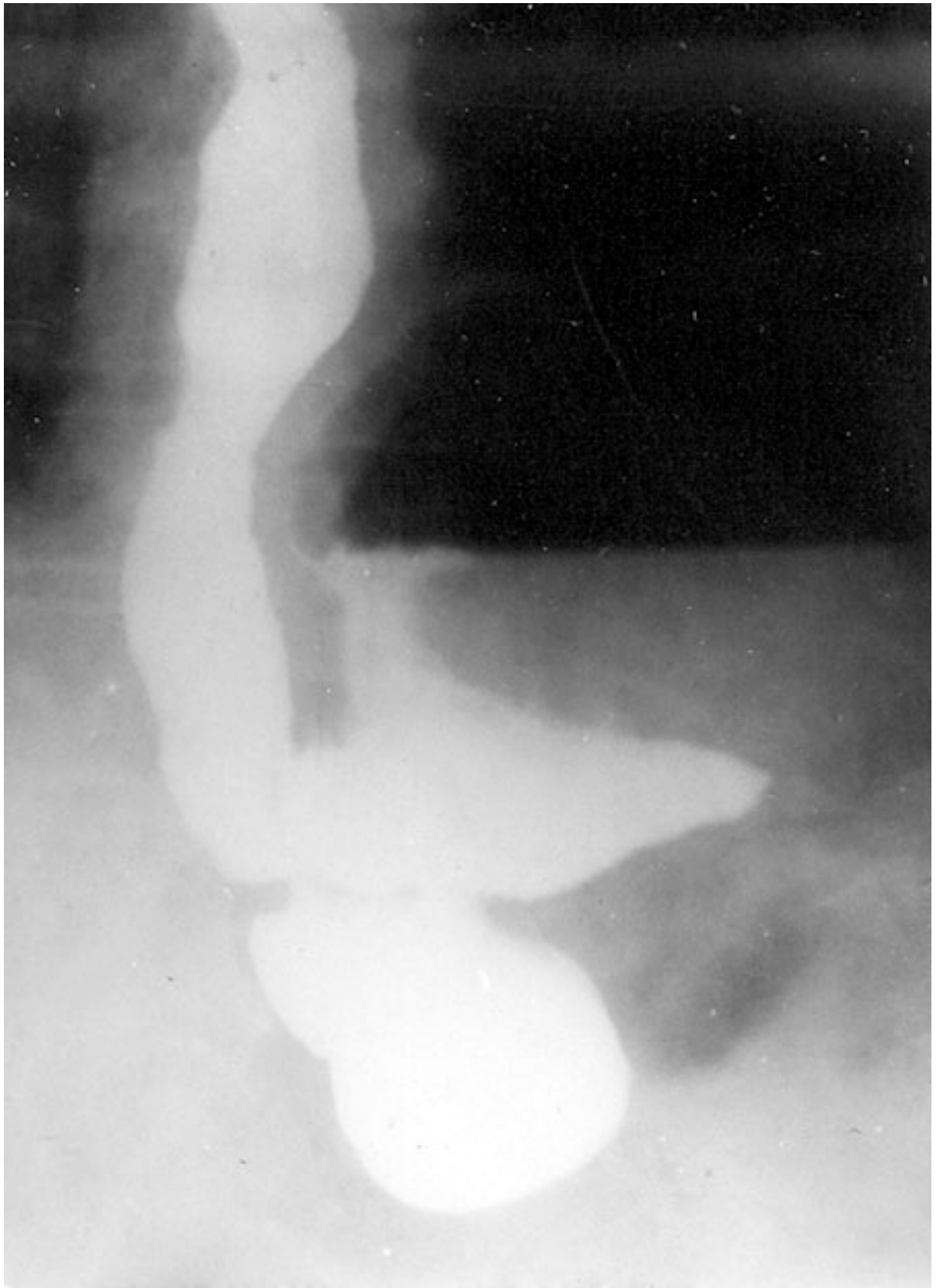

Image 4

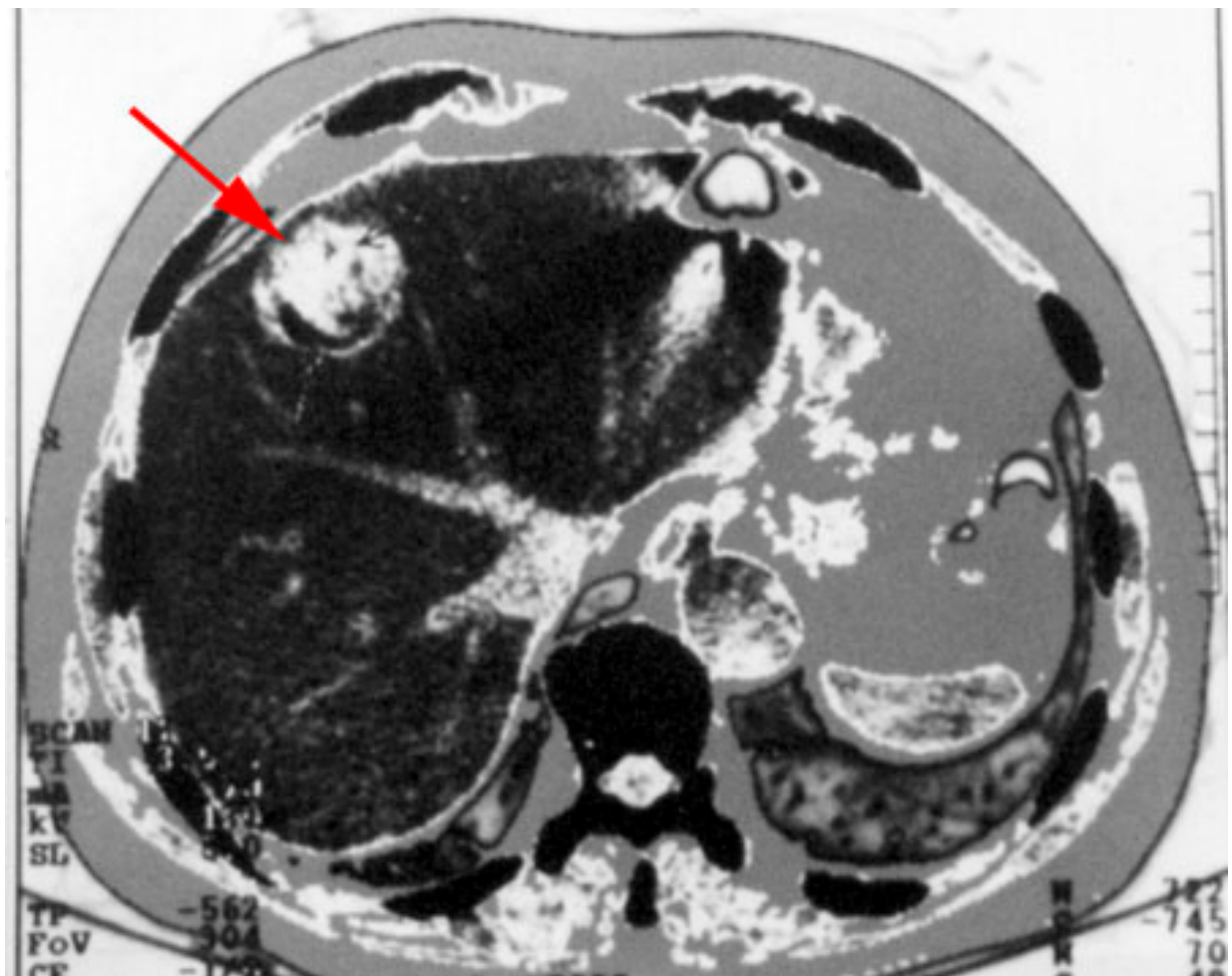


Image 5

