LESSON № 1 Examination methods of the dental patients. Anatomy of the maxillo-facial region. Structure tooth.

Examination methods of the dental patients:

drawing up clinical documents / out-patient document, clinical history etc./
- dental semiotics / complaints, anamnesis morbi, anamnesis vitae/
- clinical –instrumental observation/ visual inspection, percussion, palpation, EPT, radiographic examination etc/
- index methods
- functional methods/ rheography, polyarography etc./
- laboratory tests/ cytologic smear, bacteriologic test, biopsy etc./

Structure Tooth:

A. Grown of a tooth(corona dentis)
B. Neck of a tooth –
C. Root of a tooth

Internal tooth anatomy and tooth structure *TOOTH TISSUES*

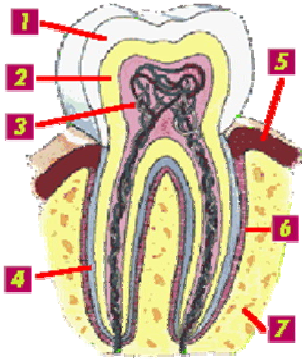

TOOTH ENAMEL (1), is the hardest of the parts of the tooth and also the hardest of all the tissues of human body. Tooth enamel is a protective tooth structure that covers the exposed part of a tooth, the crown.

DENTIN (2) or IVORY, is the tissue below the tooth enamel that forms the main mass of a tooth. It supports the tooth enamel and absorbs the pressure of eating. The dentine consists of a number of micro-fibers imbedded in a dense homogeneous matrix of collagenous proteins.

DENTAL PULP (3) , a soft connective tissue containing nerves and blood vessels, that nourish the tooth. It is the most internal structure of a tooth, surrounded by the dentine. Dental pulp is found in the soft center of the tooth, inside the pulp chamber and the root canal.

CEMENTUM (4) , is the part of tooth anatomy that covers the dentine outside of the root (under the gum line) and it is attached to the bone of the jaw with little elastic fibers. Cementum is hard as bone but not as hard as the tooth enamel.

Structure and function of periodontium *PERIODONTAL TISSUES*

PERIODONTIUM is the supporting structure of a tooth. Periodontium is the complex of soft and hard tissues that surround the tooth, keep it in place, feed and protect it.

GUMS (5), the tough pink-colored tissue that covers the bone of the jaw and supports the tooth structure inside the alveolar bone.

PERIODONTAL LIGAMENT (6), the tissue between the cementum and the alveolar bone. It consists of tough little elastic fibers that keep the tooth attached to the jaw.

ALVEOLAR BONE (7), the bone of the jaw that keeps the tooth in its place, it feeds and protects it.

The internal tooth structure is common in all types of teeth, but the external teeth parts morphology (shape of tooth crown, number and shape of roots) differs significantly between different teeth types

Primary teeth or baby teeth or deciduous teeth are called the first baby teeth of a child (sometimes also called milk teeth).

The number of baby teeth is 20 (ten at every jaw), much less than the number of the adult teeth. The primary teeth will be replaced at a baby's later age by a set of 32 permanent teeth.

Primary teeth eruption (Teething) - Baby teeth chart

Around the 8th week after conception, oval-shaped tooth buds start to form and harden in the embryo's mouth. Although the baby teeth aren't visible when a child is born, both the primary and permanent teeth are partially formed below the gums. The tooth crown develops first and after it is fully grown, the root begins to develop.

Then between about six months and 1 year old, the deciduous teeth begin to push through the gums. This process is called baby teeth eruption or teething.

A child gets his first complete set of primary teeth by the age of 3. The first baby teeth to erupt are usually the two lower front teeth.

The order of primary teeth eruption (teething age) is as shown in the following baby teeth chart :

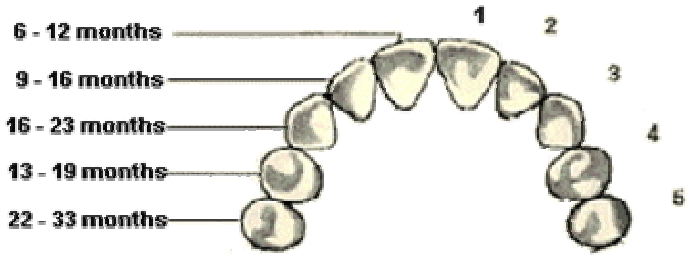

1. central incisors 2. Lateral incisors 3. Canines
4. First primolars 5. Second primolars

The baby teeth chart shows the average age that each primary tooth is expected to erupt. But not all baby teeth follow these rules. Some infants may have their first primary tooth (usually one of the bottom middle teeth) erupted as early as 3 months.

Others may reach their first birthday or more without getting their first deciduous tooth. If there is no sign of teething by this age you should ask for a pediatrician's advise. That kind of late development of primary teeth is more common in premature babies.

In some rare cases (1 every 2.000) infants are born with one or more teeth (called natal teeth) or may have teeth emerge within the first month (called neonatal teeth). A dentist should evaluate the teeth's condition, as they could be loose, interfere with feeding or irritate the baby's tongue.

The eruption of the first primary tooth marks the starting point for your child's oral hygiene. Baby teeth are susceptible to tooth decay as soon as they appear. The main dental problems related with primary teeth are : baby bottle tooth decay, thumb sucking and the early loss of primary teeth before the eruption of permanent teeth.

TOOTH MORPHOLOGY OF PRIMARY TEETH

The primary teeth are 20: ten at every jaw
8 incisors,
4 canines and
8 primary molars
The deciduous teeth of the primary dentition are smaller than the teeth of the same type in the permanent dentition, but they generally resemble in form.

There are four different types of teeth in the mouth of an adult human. The complete dentition of an adult person has 32 teeth.

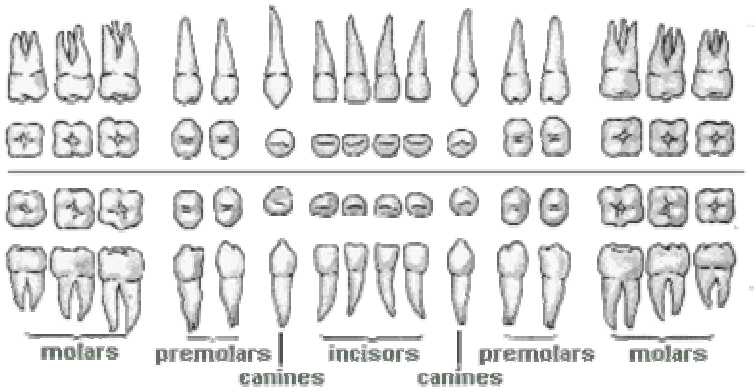

-

The adult human teeth show a morphology mainly differentiated by the shape of their upper surface (crown) and the number of the tooth roots. Individual tooth morphology is associated with the purpose of each tooth type (cutting, shredding or grinding the food).

The four different types of human teeth are :

INCISORS or Cutting teeth
- The 8 incisors are the very front human teeth with rather flat surfaces, a straight sharp horizontal edge f **CANINE teeth**
- The 4 canine teeth are very strong, pointed corner teeth for tearing and shredding, placed laterally to each lateral incisor. They are larger and stronger than the incisors.
- The canine tooth morphology is characterized by the large, conical crown which projects beyond the level of the other teeth and one single root, longer than all other teeth types.
- The upper canine teeth are sometimes called eyeteeth.or cutting and biting the food and one long, single, conical root.

PREMOLARS or Bicuspid teeth
- The 8 premolars, used for the chewing of the food, are placed lateral to and behind the canine teeth, with a flat upper surface and 1-2 roots. Their crown has two pyramidal eminences or cusps.

MOLARS or Molar teeth
- The 12 molars are the back human teeth. Molar teeth have a much different tooth morphology with large and flat upper surface and 2-4 roots. Molars is the one of types of teeth with the largest of the permanent teeth, used for the final chewing and grinding of the food before swallowing. (mola is the latin word for mill).
- The third molars are also known as wisdom teeth.

LESSON № 2 *Caries and its complications/ pulpitis, periodontitis/ Oral mucosa diseases*